

Sterile Inflammation after Radiofrequency Ablation of Osteoid Osteoma: A Case Report

Sterilní zánět po radiofrekvenční ablaci osteoidního osteomu

John Christian Parsaoran Butarbutar¹, Made Widhia Laksamana Putra¹, Elson¹, Earlene Tasya Suginawan¹, Tommy Mandagi², Alexander Samuel Partogi³, Rusli Muljadi⁴

¹Department of Orthopedics and Traumatology, Faculty of Medicine, Universitas Pelita Harapan, Siloam Hospitals Lippo Village, Tangerang, Indonesia

²Department of Orthopedics and Traumatology, Faculty of Medicine, Universitas Sumatera Utara, Medan, Sumatra Utara, Indonesia

³Department of Anesthesiology, Faculty of Medicine, Universitas Pelita Harapan, Siloam Hospitals Lippo Village, Tangerang, Indonesia

⁴Department of Radiology, Faculty of Medicine, Universitas Pelita Harapan, Siloam Hospitals Lippo Village, Tangerang, Indonesia

✉ **dr. John Christian Parsaoran Butarbutar, M.D.** | john.butarbutar@lecturer.uph.edu | www.uph.edu

Received | Doručeno do redakce | Doručené do redakcie 8. 1. 2023

Accepted | Prijato po recenzii | Prijaté po recenzii 3. 2. 2023

Abstract

Introduction: Osteoid osteoma is a benign bone tumor with the classical characteristic of pain that subsides significantly with the use of nonsteroidal anti-inflammatory drugs. When conservative therapy fails, a surgical approach is then recommended. Radiofrequency ablation (RFA) has become more widely used compared to open resection due to fewer serious postoperative complications. But it is still important that the complications of RFA be recognized and addressed. **Case report:** We present a case of a 22-year-old man with acute pain on his left shin, accompanied by signs of localized inflammation. The clinical findings and radiology support the diagnosis of osteoid osteoma. A surgical intervention with percutaneous radiofrequency ablation was performed. However, post-operatively, the patient complains of prolonged fluid discharge from the surgical site. Following the biopsy and debridement surgery, both specimen culture and histopathology results revealed sterile inflammation with no specific process. **Conclusion:** RFA has become the most popular treatment of choice for osteoid osteoma, but it still comes with complications, most commonly involving subcutaneous bones such as the tibia. In conclusion, extra caution is needed when treating subcutaneously located bones with RFA.

Key words: osteoid osteoma – radiofrequency ablation – sterile inflammation

Introduction

Osteoid osteoma is a small, benign, but painful lesion, most often seen in the long bones of the lower extremity, more often diaphyseal than metaphyseal [1,2]. The use of aspirin and nonsteroidal anti-inflammatory drugs (NSAIDs) has been shown to reduce the natural course of the disease by 2 years. However, prolonged use of NSAIDs has gastrointestinal and kidney side effects. A surgical approach is suggested for patients

with severe pain that is unresponsive to NSAIDs or for patients with a risk of prolonged use of NSAIDs [3–5].

Radiofrequency ablation (RFA) has been shown to have more advantages than en bloc resection surgery [2,6,7]. RFA provides a better precision without sacrificing a large amount of healthy tissue, thus enabling a shorter hospital stay and recovery time. However, there may be complications associated with RFA, which include skin burns, site infection, nerve injury, hema-

toma, and necrosis of the surrounding tissue [6]. We present a case of persistent clear-fluid discharge after RFA of tibial osteoid osteoma.

Case report

A 22-year-old man presented with left shin pain 10 days prior to the hospital visit. It was initially intermittent but had gotten worse to the point where he couldn't bear weight and the pain was causing sleep disturbances at night. He had a history of a fracture at the same site 10 years ago and underwent flexible nail fixation that was removed after 2 months.

Clinical findings

Examination showed a visual analog pain scale of 7–8, swelling on the proximal left cruris with exquisite tenderness and mild inflammation but no skin discoloration, sinus or knee effusion. The range of motion of the left knee was limited due to severe pain.

Diagnostic assessment

An X-ray showed a well-defined radiopaque nodule at 1/3 of the proximal left tibia with a central lucent area (Figure 1.1). With a suspected tumor diagnosis, an MRI was taken and showed a nidus in the left tibial diaphysis, 1/3 proximal to the anterolateral aspect, with extensive surrounding bone marrow edema, a narrow transition zone, and focal thickening of the perilesional cortex, with no soft tissue extension and matrix mineralization. These findings suggest osteoid osteoma (Figure 1.2).

Therapeutic intervention

The patient underwent CT-guided RFA. The procedure was performed in an aseptic condition with the patient in a supine position under spinal anesthesia with 12.5 mg of heavy bupivacaine (0.5 %) and 25 mcg of fentanyl. The lesion site was confirmed by spot CT imaging (Figure 2). A tibial entry point was marked on the medial side of the tibial cortex (Figure 3.1). A small skin incision was made and the dissection continued with blunt force. Cortex was drilled with a 3.2 mm drill bit.

A coaxial biopsy needle was inserted and tapped until it advanced just at the edge of the nidus. A CT scan with an axial view was performed to confirm the nidus location. Then, the inner stylet was retracted, the cannula advanced forward, and another spot CT was obtained to confirm (Figure 3.2). A tissue biopsy from the nidus was collected and sent for histopathological examination. Later, histopathological examination revealed a nidus of woven bone and osteoid with a surrounding reactive zone. Afterwards, a 20-G radiofrequency electrode (COSMAN, CSK-5, Cosman Medical, Inc., USA) was inserted through the medial tibial cortex to the nidus (Figure 4). Other spot CT images were obtained to confirm the tip of the electrode's position. The electrode is connected to the RF generator (we use COSMAN G4, Cosman Medical, Inc., USA), and ablation is performed by increasing the temperature to 90 °C for a total of 6 minutes at 363-ohm impedance. After ablation, a local anesthetic was injected for pain relief, and a sterile pressure gauze was applied.

Follow-up and outcomes

The patient was admitted after the procedure for pain control with analgesics and bed rest. The patient was discharged with significant pain reduction the day after. Histopathology results showed trabecular fragments

Figure 2 | (A) Localization of the lesion (B) CT Scan Findings: focal cortical lucencies with sclerotic margins and a nidus (diameter +/- 0.25), in the cortex diaphysis 1/3 proximal to the anterior lateral aspect of the left tibia

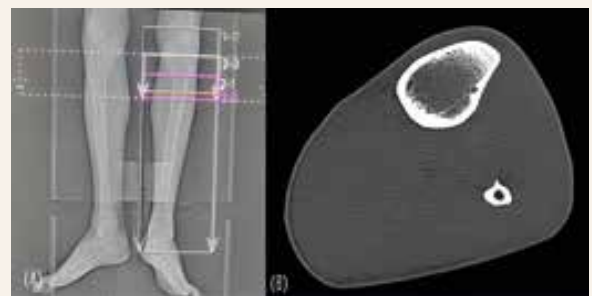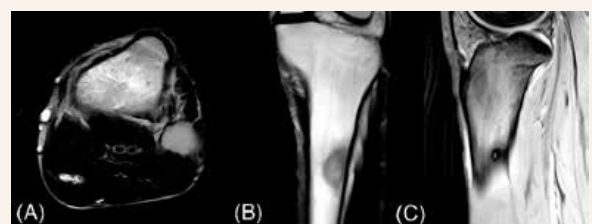


Figure 1 | 1.1 Plain Xray of the left tibia showed the presence of a nodule on (A) AP and (B) lateral view (yellow arrow). 1.2 An MRI Sequence T1WI and STIR of the left tibia revealed a nidus

Figure 1.1

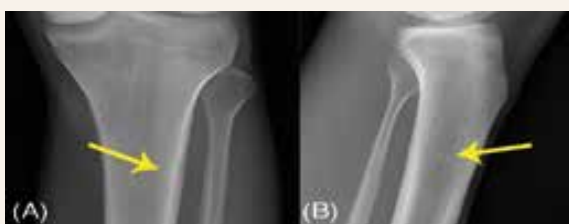

Figure 1.2



of bone with acute and chronic inflammation, consistent with osteoid osteoma. During the first 2 weeks post-procedure, the patient still experienced mild discomfort and a thick, turbid discharge from the incision site. The discharge was then taken to a culture facility and treated with wound irrigation and drainage. While waiting for the culture result, an empiric antibiotic was given. The result showed that *Staphylococcus aureus* was present, so the antibiotic was kept going for 3 weeks.

Two months after the procedure, the patient returned, still complaining of a clear-fluid discharge from the incision site. Pain and other complaints were not present. Physical examination showed a sinus on the incision site with serous discharge. An X-ray was then obtained, showing a radiolucent nodule on 1/3 medial of the tibia following ablation of osteoid osteoma on the left tibial bone (Figure 5.1).

Due to the concern of a iatrogenic osteomyelitis process, the patient then underwent debridement surgery. During surgery, hyperpigmentation was found around the skin of the incision site, and subcutaneous tissue approximately 1 cm in diameter was excised (Figure 5.2). Then, the drilling hole from the previous procedure was enlarged. On curettage of the intra-medullary bone marrow, no pus or pathological tissue was found. Specimens were taken for culture and histopathology examinations. The patient was given antibiotic therapy for 14 days after surgery. Histopathology results showed granulomatous inflammation with no signs of malignancy and no clear specific process in this specimen. Culture also showed a negative result.

Discussion

Osteoid and woven bones surrounded by a halo of reactive bone form osteoid osteoma. Osteoid osteoma occurs in a younger population, usually between the ages of 10 and 35, and is more commonly found in men than women, with an approximately 4:1 ratio [1,2,5,6].

Classical symptoms include pain that worsens at night and is relieved by non-steroidal anti-inflammatory drugs (NSAIDs). Non-steroidal anti-inflammatory drugs inhibit the synthesis of prostaglandins by the surrounding osteosclerosis of the nidus as part of the pathophysiology. [8] Pain is initially described as a dull ache sensation but may progress to severe local pain with swelling, erythema, and tenderness if the lesion is located in the subcutaneous bone. When in close proximity to a joint, they can result in stiffness and joint effusion [6]. In this presented case, the patient complained of severe pain on the left leg that worsened at night, with swelling, erythema, and tenderness on the proximal left leg consistent with osteoid osteoma but not responsive to NSAIDs. We also found knee joint stiffness but no joint effusion.

On radiograph, osteoid osteoma is usually characterized by a circular or ovoid cortical lucency with a diameter of less than 1.5 cm, surrounded by some degree of sclerosis.[6] A CT scan is the best imaging modality to locate the nidus. Radionuclide bone scanning can also be utilized, but it has low specificity [2]. Magnetic resonance imaging (MRI) is typically used to visualize the surrounding tissues, which serves to rule out other differential diagnoses. However, findings on

Figure 4 | (A) The RF electrode is then inserted, with its tip directed to the center of the nidus. The cannula is partially retracted over the electrode. **(B)** Spot CT images are again obtained to confirm the position of the electrode




Figure 3 | 3.1 A Spot CT image is obtained to confirm the insertion point and skin marking. **3.2** A coaxial biopsy needle was then inserted into the nidus. The drill tip is positioned at the edge of the nidus, and the cannula is advanced over the drill. Then the drill is retracted, and a CT scan is performed to confirm that the cannula is correctly in place

Figure 3.1

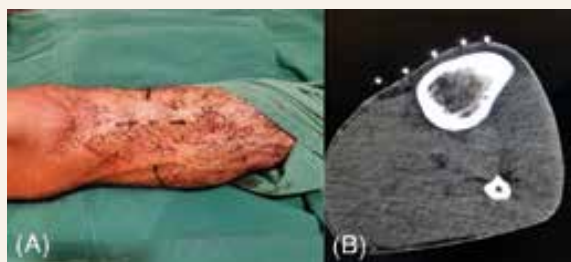
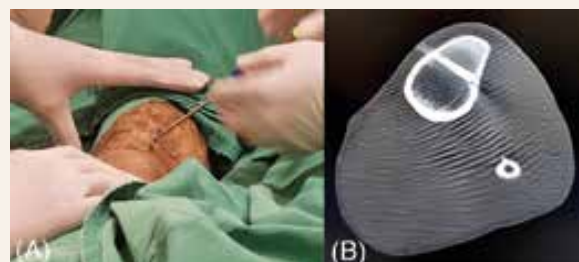


Figure 3.2



MRI are not specific and may be visually similar to conditions such as stress fracture, osteomyelitis with sequestrum, Brodie abscess, chondroblastoma, or osteoblastoma [6]. The radiograph and MRI in this presented case are consistent with osteoid osteoma. There were no signs of osteomyelitis or a fracture. Nidus was found with a central lucent area on the proximal third of the left tibia.

Osteoid osteoma could heal spontaneously within 1.5 to 6 years. The natural course of disease can be reduced by 2–3 years with the use of aspirin and NSAIDs. However, this treatment exposed the patient to the side effects of the prolonged use of NSAIDs. For patients with severe pain and unresponsiveness to NSAIDs, surgical options are often considered, including open surgery and percutaneous ablation [3–5]. Open ‘En Bloc Resection’ for osteoid osteoma entails some disadvantages, as it may result in the resection of a large amount of normal bone to completely excise the tumor, which leaves the bone vulnerable to fracture, internal fixation, and bone grafting. Even with a guiding wire, tetracycline labeling, and intraoperative scintigraphy, it is often difficult to localize the nidus [7]. The postoperative hospital stay is usually between 3 and 5 days, followed by a partial weight-bearing activity within 1–6 months from the surgery.

RFA has been considered a treatment of choice. With CT-scan guidance, RFA provides precise localization of the nidus. In addition, it is also associated with shorter hospital stays and recovery times, and daily activities may be resumed immediately without the use of a cast, splint, or other external supportive devices [2,6]. Due to the severe and disabling pain, we decided that surgery with RFA was the best treatment course for the patient.

Radiofrequency ablations include some complications, including skin burns, tissue necrosis, soft tissue infection, vasomotor instability, tendinitis, and hematoma. As mentioned by a study conducted by Yunus

Oc et al., the complications mentioned above are more likely to be observed in lesions found on the tibial bone [1].

Discharge was found 2 weeks post procedure and was treated with antibiotics due to a positive Staphylococcus infection, but even with sufficient antibiotics, continuous discharge was present even after 2 months post procedure. On debridement surgery, hyperpigmentation of subcutaneous tissue was found, and the culture result was negative, therefore the conclusion established sterile inflammation due to soft tissue thermal necrosis. We suspected the previous culture was contaminated by the normal flora of the skin. We found three similar cases reporting the same complaints as our patient post-procedure, all with a tibial lesion, and one case requiring surgical debridement due to a fistula [10–12]. A higher risk of skin necrosis was found in osteoid osteomas located in superficial bones. To avoid this problem, the outer cannula should be pulled back to about 1 cm above the non-insulated tip of the coagulation cannula [12].

The lack of real-time guidance is one of the technical limitations of a spot CT in needle guidance procedures. Another author suggested the use of CT-fluoroscopy to obtain a highly resolved visualization of bone structures and a more rapid frame rate, which would allow treatment under real-time fluoroscopy [2,5].

Conclusion

The treatment of osteoid osteoma has shifted throughout the years, with RFA as one of the most preferred treatment procedures in comparison to tumor resection, due to its efficient recovery time and process. However, RFA presents some complications, including thermal necrosis of the surrounding tissue, which is more common in subcutaneous bones such as the tibia. Because of this, RFA must be done with extra care when the tibia has osteoid osteoma.

Figure 5 | 5.1 A follow-up X-ray revealing the post-ablation site.
5.2 Hyperpigmentation is found on the subcutaneous tissue intraoperatively

Figure 5.1

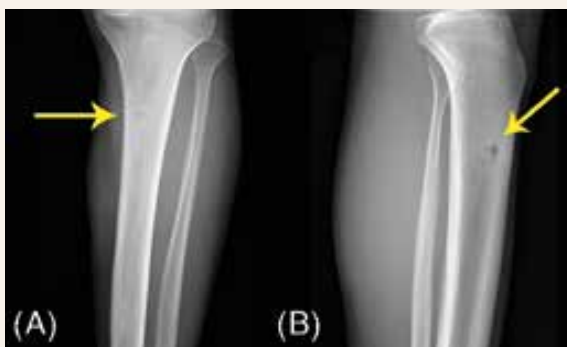
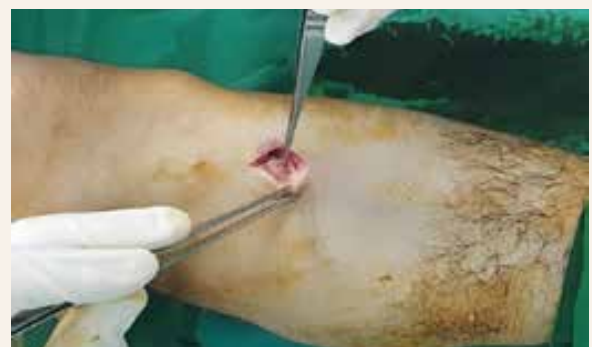
Figure 5.2



Clinical Message

The doctor should know that RFA, which is one of the most commonly used treatments, can cause some problems, such as thermal necrosis of the surrounding tissue, which is more likely to happen in bones that are close to the skin, like the tibia.

Acknowledgment

None

Conflict of interest

The authors declare that they have no competing interests.

Financial support and sponsorship

This research did not receive any specific grant from funding agencies in the public, commercial or not-for-profit sectors.

Informed consent

The patient has given his consent for the case report to be published. A detailed written informed consent was obtained for publication of the data, images and treatment related documents without any objection.

Institutional ethical committee approval

Not applicable.

Authors contribution

JCPB is an orthopedic surgeon who evaluated and treated the patient and also contributed to the writing, review, and editing of the manuscript. E, ETS, and MWLP contributed to the original writing, editing, and referencing of the manuscript, and also to editing of the images and radiographs. TM contributes to the evaluation and referencing of the manuscript. ASP is an anesthesiologist

who joined the procedure to treat the patient. RM is a radiologist who joined the procedure to treat the patient.

References

1. Oc Y, Kilinc BE, Cennet S et al. Complications of Computer Tomography Assisted Radiofrequency Ablation in the Treatment of Osteoid Osteoma. *Biomed Res Int* 2019; 2019: 4376851. Dostupné z DOI: <<http://dx.doi.org/10.1155/2019/4376851>>.
2. Çakar M, Esenyel CZ, Seyran M et al. Osteoid Osteoma Treated with Radiofrequency Ablation. *Adv Orthop* 2015; 2015: 807274. Dostupné z DOI: <<http://dx.doi.org/10.1155/2015/807274>>.
3. Moberg E. The natural course of osteoid osteoma. *J Bone Joint Surg Am* 1951; 33 A(1): 166–170.
4. Golding JS. The Natural History of Osteoid Osteoma; with a report of twenty cases. *J Bone Joint Surg Br* 1954; 36-B(2): 218–229. Dostupné z DOI: <<http://dx.doi.org/10.1302/0301-620X.36B2.218>>.
5. Noordin S, Allana S, Hilal K et al. Osteoid osteoma: Contemporary management. *Orthop Rev (Pavia)* 2018; 10(3): 7496. Dostupné z DOI: <<http://dx.doi.org/10.4081/or.2018.7496>>.
6. Motamedi K, Katz MD, Earl W et al. Thermal Ablation of Osteoid Osteoma : Overview and step-by-step guide. *Radiographic* 2009; 29(7): 2127–2141. Dostupné z DOI: <<http://dx.doi.org/10.1148/rg.297095081>>.
7. Rosenthal DI, Hornicek FJ, Wolfe MW et al. Percutaneous radiofrequency coagulation of osteoid osteoma compared with operative treatment. *J Bone Joint Surg Am* 1998; 80(6): 815–821. Dostupné z DOI: <<http://dx.doi.org/10.2106/00004623-199806000-00005>>.
8. Greco F, Tamburrelli F, Ciabattoni G. Prostaglandins in osteoid osteoma. *Int Orthop* 1991; 15(1): 35–37. Dostupné z DOI: <<http://dx.doi.org/10.1007/BF00210531>>.
9. Cantwell CP, O'Byrne J, Eustace S. Radiofrequency ablation of osteoid osteoma with cooled probes and impedance-control energy delivery. *Am J Roentgenol*. 2006; 186(5 Suppl): S244-S248. Dostupné z DOI: <<http://dx.doi.org/10.2214/AJR.04.0938>>.
10. Finstein JL, Hosalkar HS, Ogilvie CM et al. Case reports: an unusual complication of radiofrequency ablation treatment of osteoid osteoma. *Clin Orthop Relat Res* 2006; 448(448): 248–251. Dostupné z DOI: <<http://dx.doi.org/10.1097/01.blo.0000214412.98840.a1>>.
11. Lyon C, Buckwalter J. Case report: full-thickness skin necrosis after percutaneous radio-frequency ablation of a tibial osteoid osteoma. *Iowa Orthop J* 2008; 28: 85–87.
12. Pinto CH, Taminiau AHM, Vanderschueren GM et al. Perspective. Technical considerations in CT-guided radiofrequency thermal ablation of osteoid osteoma: Tricks of the trade. *Am J Roentgenol* 2002; 179(6): 1633–1642. Dostupné z DOI: <<http://dx.doi.org/10.2214/ajr.179.6.1791633>>.